

Polymorphic ventricular tachycardia in acute myocardial infarction treated by thrombolysis: reperfusion, complication or iatrogenic sign?

Mariana FLORIA, MD; Ciprian REZUS, MD^a; Mirela CIUTEA, MD^a;
Eva ORBAN, MD; Iuliana MARIAN, MD; Lacramioara PANTARU, MD;
Valentin AMBARUS, MD^a

^{2nd}Medical Clinic, "St. Spiridon" University Hospital, Iasi, Romania

^{a 3rd}Cardiology Clinic, "St. Spiridon" University Hospital,
and "Gr.T. Popa" University of Medicine and Pharmacy, Iasi, Romania

ABSTRACT

The QT interval prolongation may determine a type of polymorphic ventricular tachycardia named torsades de pointes. This ventricular arrhythmia could also appear after thrombolysis of acute myocardial infarction.

Case reports. A 57 years old man was admitted 2 hours after the onset of a posterior-inferior-lateral acute myocardial infarction (reinfarction). He underwent pharmacological revascularization with reteplase. In the first 24 hours after thrombolysis a sustained polymorphic ventricular tachycardia was unregistered after the second dose of a quinolone recommended for a urological problem. Despite of the normal serum potassium and magnesium QTc suffered an augmentation from 400 ms to 480 ms. After beta-blocker augmentation dose and the antibiotic changing, ventricular arrhythmia disappeared without repetition during hospitalization. This ventricular tachycardia was considered precipitated by the quinolones therapy by increasing of QTc interval. It could also be considered a reperfusion sign or a complication of the reinfarction in the same area, which means different therapeutical solutions.

Key words: polymorphic ventricular tachycardia, quinolones, thrombolysis, acute myocardial infarction.

Address for correspondence:

Mariana Floria, MD, 2ndMedical Clinic, "St. Spiridon" University Hospital, 1 Independentei Blvd., Iasi, Romania
email address: floria_mariana@yahoo.com

CASE PRESENTATION

A male patient 57 years old was admitted in the Emergency Department with anterior thoracic pain approximately 2 hours after the onset. He was smoker and chronic consumer of alcohol. From his pathological medical history, we mention the following: 3rd degree essential hypertension complicated by a stroke that led to a left hemiparesis in 2005 and acute posterior-inferior myocardial infarction treated conservatively in 2007. The patient followed an intermittent treatment with calcium blockers (dihydropyridine class). The electrocardiogram performed at patient admission is presented in FIGURE 1.

As diagnostic criteria for acute myocardial infarction (reinfarction) in the posterior-inferior-lateral area were fulfilled from the clinical, electrocardiographically and enzymatic points of view, the pharmacological thrombolysis with reteplase was performed. After the thrombolysis was finished (FIGURE 2) the pain disappeared and electrocardiographically were registered monomorphic premature ventricular contractions systematized in bigeminy periods, some of them being precocious. The ventricular ectopic beats disappeared after the initiation of the therapy with beta-blocker (100 mg metoprolol), associated with anticoagulant and antiplatelet therapy and statins. The presence of a urinary infection favoured by the benign hyperplasia of the prostate imposed the therapy with quinolone (ciprofloxacin 400 mg/day). During the first 24 hours after the thrombolytic therapy, the patient was ECG monitored. After the administration of the second dose of quinolone in intravenous perfusion, at 14 hours after the end of the reteplase his QTc prolonged to 480 ms from 400 ms and a symptomatic (dizziness) repetitive unsustained polymorphic ventricular tachycardia (FIGURE 3) started. Biologically, the serum potassium and magnesium level were within normal limits. In the given clinical context, the ventricular rhythm disorder was interpreted as a consequence of the QT prolongation triggered by the quinolone, and the antibiotic was replaced. In addition, the beta-blocker dose was increased from 100 mg to 200 mg, after 5 mg intravenous dose administration. After the quinolone interruption the QTc interval dropped to 400 ms and, dur-

ing the entire hospitalization period, the patient had no more ventricular rhythm disorder. □

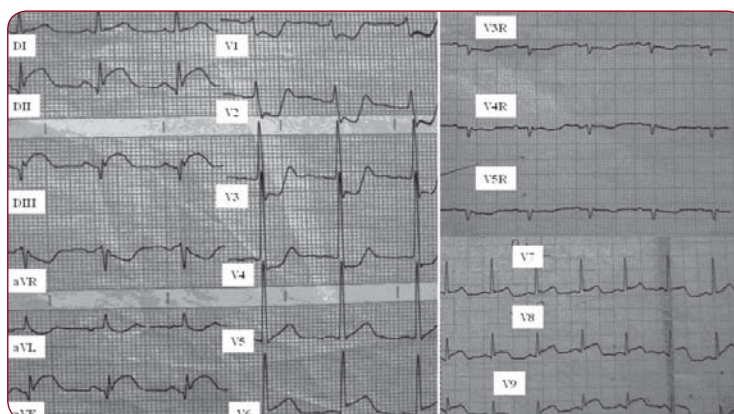


FIGURE 1. The 12 leads ECG trace at admission shown direct signs of ST elevation myocardial infarction (STEMI) in inferior, posterior and lateral leads

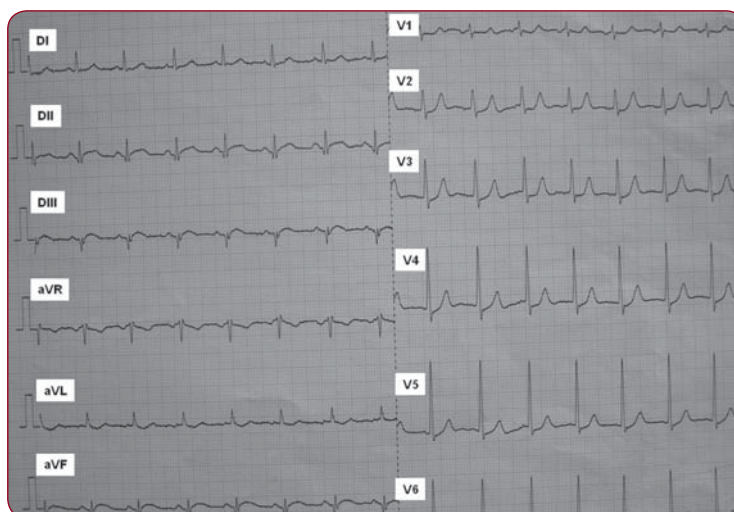


FIGURE 2. The 12 leads ECG trace after the end of the thrombolytic therapy shown significantly decreasing of the ST segment elevation (QTc=400 ms)

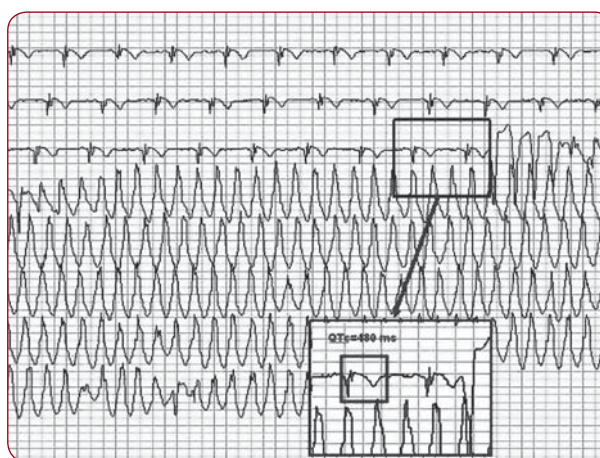


FIGURE 3. The polymorphic ventricular tachycardia on a single lead ECG (on monitoring system)

DISCUSSIONS

This ventricular arrhythmia naturally raised the question: how should be considered and especially how should be treated? A reperfusion sign, a complication of the prior or of the current infarction or an iatrogenic problem due to concomitant administration of a quinolone? As reperfusion arrhythmia, set within the first 24 hours after the thrombolytic, no prophylactic treatment is necessary, though it is symptomatic. As arrhythmia triggered by the older infarction scar favoured by the new one, a treatment to control it would be imperious and the most indicated is the amiodarone therapy. In rare, particular situations, the ciprofloxacin prolongs the QT interval and may cause torsades de pointes. This could be another explanation for this ventricular arrhythmia, which asks a different therapeutic solution.

1. Ventricular tachycardia as reperfusion arrhythmia or complication of re-infarction in the same area

Ventricular tachycardia is a reperfusion sign within the first 24 hours after the thrombolytic therapy. The characteristics of a reperfusion arrhythmia are: 3 or more ventricular ectopic beats, frequency between 50 and 120/min and the onset after a long coupling interval. The last characteristic differentiates the accelerated idioventricular rhythm from a slow ventricular tachycardia that begins after a short coupling interval, during the first 24 hours after the reperfusion. The accelerated idioventricular rhythm could appear even in the absence of the reperfusion. In this clinical case, the rhythm disorder begun after a short coupling interval, during the first 24 hours after the reperfusion, but the rate of about 200/min is clearly an argument against to the reperfusion arrhythmia hypothesis. Nevertheless the appearance of the ventricular tachycardia during the first 24 hours after the thrombolytic therapy though in a particular context (on the background of a long QT interval and re-infarction) could be deemed a reperfusion arrhythmia. After the administration of the thrombolytic therapy, the presence of some precocious premature ventricular contractions would plead for it, but the onset of the tachycardia through a widened QRS is against this, suggesting actually the consequence of the prolongation of the QT interval.

The presence of a necrosis area given by the posterior-inferior infarction in 2007, treated

conservatively, explains the existence of a possible circuit around it and the appearance of a re-entry arrhythmia. But tachycardia is usually monomorphic (not polymorphic) and the patient had not the previous syncope. Such hypothesis could impose the implementation of a prophylactic therapy, especially if late potentials are confirmed after the recovery from the myocardial infarction. An electrophysiological study may bring additional information about the ventricular vulnerability secondary to the scar of the posterior-inferior wall. Anyway the coronarographic exam and the electrophysiological study, the most important investigations for real answers to these questions, were delayed by the patient. Unfortunately the registration of a single ECG lead during the ventricular tachycardia did not allow to obtain more information (about the tachycardia origin) like as 12 leads ECG.

2. Ventricular tachycardia as consequence of iatrogenic prolongation of the QT interval

Torsades de pointes is a polymorphic ventricular tachycardia associated with the QT interval prolongation. There are several classes of drugs (cardiac and non-cardiac) that can prolong the QT interval, and the antiarrhythmics and antipsychotics are part of the high probability class. The antibiotics such as azithromycin, ciprofloxacin and clindamycin are included in the category unlikely to induce the QT prolongation according to an expert's opinion consensus (1). In particular circumstances are quoted cases of the QT interval prolongation and torsades de pointes induction under therapy with ciprofloxacin (2).

The risk factors for the long QT interval prolongation are: the female gender, bradycardia, strong hypopotassemia and hypomagnesemia, recent conversion of an atrial fibrillation episode especially with anti-arrhythmics that prolong QT interval, congestive cardiac failure, digitalis therapy, high concentration of drugs or their rapid infusion even if they don't extend QT very much, a subclinical long QT syndrome or the polymorphism of some ionic channels (3). The first nine quoted factors do not correspond to the presented clinical case. The last two conditions are difficult to demonstrate in current practice, as genetic tests are necessary.

Torsades de pointes determined by the prolongation of the QT interval secondary to the non-cardiac drugs administration is a rare but potentially life threatening manifestation. The

manner in which the QT interval is related to the safety of the administration of the non-cardiac drugs and how physicians can integrate better pre-clinical and clinical information in the evaluation of the risk profile of such drugs, remain two questions to which the answer is still searched. The QT interval as electrocardiographically manifestation of the ventricular depolarisation and repolarisation duration is a surrogate of the pro-arrhythmic potential of drugs. This is measured from the beginning of the QRS complex up to the T wave end. There is no consensus regarding the manner of calculation of the corrected QT interval (QTc), as the specialized literature contains several formulas. In this study, it was calculated according to the Bazett formula: $QTc = QT/RR^{1/2}$, using the DII derivation and calculating the mean of (3) values (4). Other calculation formula is Fridericia's (the QT interval divided by the cube of the RR interval) or the Framingham lineal regression equation (5,6). The upper normal limit using the Bazett formula is 450 ms in men and 470 ms in women (7). The relation between the QTc prolongation degree and the peak distortion risk is not known; as such a threshold value is impossible to find out. Most cases of torsades de pointes were reported by the literature in patients with an uncorrected QT interval of over 500 ms, which is why it's increasing to over 500 ms must be a warning signal (8).

Quinolones represent a group of antibiotics whose class effect is pro-arrhythmias in conditions of major electrolytic disorders. The appearance of peak distortion upon the administration of these antibiotics may be predicted through the increase of the dispersion of repolarisation and the appearance of the triangular aspect of the action potential. All quinolones

induce the peak distortion in case of severe hypokalemia, with moxifloxacin as class leader, followed by ciprofloxacin (9).

The QRS duration and the QT duration are associated with the mortality during a myocardial non-fatal infarction, regardless of age, of the function of the left ventricle and the extension of the coronary disease (10). In the clinical presented case, a new infarction on a necrosis area previously constituted, with high arrhythmogenic probability, associated with iatrogenic prolongation of the QT interval is a particularity. This facilitated the appearance of the ventricular rhythm disorder. On the contrary, the replacement of the antibiotic as the presence of the reperfusion and the beta-blockers therapy either might contribute to the QT decreasing. Nowadays is known that therapy with beta-blockers and not with antiarrhythmics (like amiodarone) reduce the morbidity and mortality in the myocardial infarction. Thus, in this case, the beta-blocker therapy instead of the amiodarone therapy led to a favourable result. □

CONCLUSION

Polymorphic ventricular tachycardia appeared within the first 24 hours after the thrombolytic therapy and considered an iatrogenic complication, secondary to the quinolone therapy, which probably determined the QT prolongation. The treatment with amiodarone and the continuation of the therapy with quinolone could have determined the rhythm disorders worsening by more prolongation of the QT interval. Even without the electrophysiologic study and coronarographic exam (not with a widely accessibility), our therapeutic solution was appropriate, in the given clinical context. □

REFERENCES

1. Al-Khatib SM, La Pointe NMA, Kramer JM et al. – What Clinicians Should Know About the QT Interval. *JAMA* 2003; 289:2120-2127
2. Flanagan MC, Mitchell ES, Haigney MC – Ciprofloxacin-induced torsades de pointes. *Int J Cardiol* 2006; 113(2):239-241
3. Roden DM – Drug-induced prolongation of the QT interval. *N Engl J Med* 2004; 350(10):1013-1022
4. Milne JR, Ward DE, Spurrell RA et al. – The ventricular paced QT interval: the effects of rate and exercise. *Pacing Clin Electrophysiol* 1982; 5:352-358
5. Hnatkova K, Malik M – "Optimum" formulae for heart rate correction of the QT interval. *Pacing Clin Electrophysiol* 1999; 22:1683-1687
6. Aytemir K, Maarouf N, Gallagher MM, Yap YG et al. – Comparison of formulae for heart rate correction of QT interval in exercise electrocardiograms. *Pacing Clin Electrophysiol* 1999; 22:1397-1401
7. Committee for Proprietary Medicinal Products (CPMP) – Points to consider: the assessment of the potential for QT interval prolongation by non-cardiovascular medicinal products. European Agency for the Evaluation of Medicinal Products, England, London, 1997
8. Bednar MM, Harrigan EP, Anziano R et al. – The QT interval. *Prog Cardiovasc Dis* 2001; 43:(Suppl.):25-33
9. Milberg P, Hilker E, Ramtin S et al. – Proarrhythmia as a class effect of quinolones: increased dispersion of repolarization and triangulation of action potential predict torsades de pointes. *J Cardiovasc Electrophysiol* 2007; 18(6):647-654
10. Artar NM, Wong K, Groves GD et al. – Clinical Implications of QRS Duration and QT Peak Prolongation in Patients with Suspected Coronary Disease Referred for Elective Cardiac Catheterization. *Ann Noninvasive Electrocardiol* 2008; 13(2):106-112